

CASE REPORT

Ludwig's Angina: Emergency Treatment

¹KA Kamala, ²S Sankethguddad, ³SG Sujith

ABSTRACT

Ludwig's angina is a form of severe diffuse cellulitis that presents an acute onset and spreads rapidly, bilaterally affecting the submandibular, sublingual, and submental spaces resulting in a state of emergency. Early diagnosis and immediate treatment planning could be a life-saving procedure. Here, we report a case of Ludwig's angina successfully treated by surgical decompression under antibiotic coverage.

Keywords: Ludwig's angina, Management, Odontogenic infection.

How to cite this article: Kamala KA, Sankethguddad S, Sujith SG. Ludwig's Angina: Emergency Treatment. J Health Sci Res 2017;8(1):46-48.

Source of support: Nil

Conflict of interest: None

INTRODUCTION

Ludwig's angina is a rapidly progressive, potentially fulminant cellulitis involving the sublingual, submental, and submandibular spaces. It may or may not involve parapharyngeal space.¹

The word Angina is derived from the Latin word *angere* which means to strangle. Ludwig's angina was coined after the German physician, Wilhelm Friedrich von Ludwig, who first described this condition in 1836 as a rapidly and frequently fatal progressive gangrenous cellulitis and edema of the soft tissues of the neck and floor of the mouth.² Other synonyms include angina ludovici, cyananche, carbunculus gangraenosus, morbus strangulatorius and angina maligna.³

Despite the recent advances in therapy, rare and potentially life-threatening complications may still arise from time to time, and, as a result, account for significant morbidity and mortality. We present a case of Ludwig's angina, successfully managed at our hospital, with a brief review.

¹Associate Professor, ^{2,3}General Practitioner,

¹Department of Oral Medicine and Radiology, Krishna Institute of Medical Sciences Deemed University, Karad, Maharashtra, India

^{2,3}Department of Periodontology, Sri Manjunatha Dental Clinic Dharwad, Karnataka, India

Corresponding Author: KA Kamala, Associate Professor Department of Oral Medicine and Radiology, Krishna Institute of Medical Sciences Deemed University, Karad, Maharashtra India, e-mail: kamala.kamble@rediffmail.com

CASE REPORT

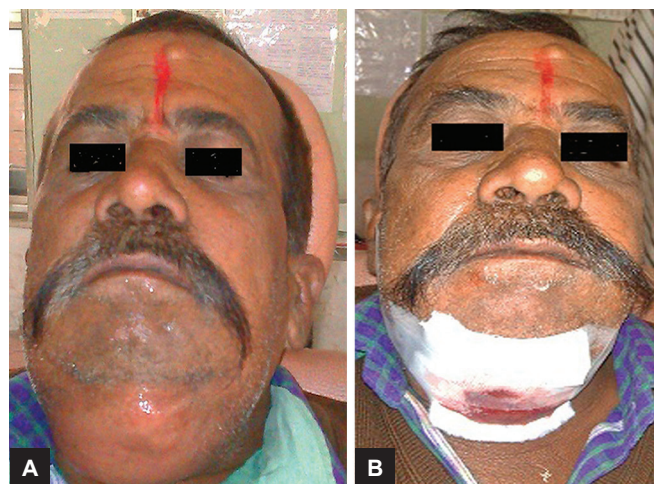A 55-year-old male presented with a chief complaint of inability to open the mouth, pain, and swelling in relation to the lower jaw and neck since a day. Patient revealed history of pain in left lower tooth region 4 days back and has taken treatment from local doctor (Tab. Combiflam twice a day), but the pain had not subsided. Past medical, dental, and family histories were noncontributory.

On physical examination, he had respiratory distress and was toxic in appearance and his vital signs were monitored immediately. His temperature was 101.3°F with a pulse rate of 104 beats per minute, blood pressure of 140/90 mmHg, and a respiratory rate of 27 breaths per minute.

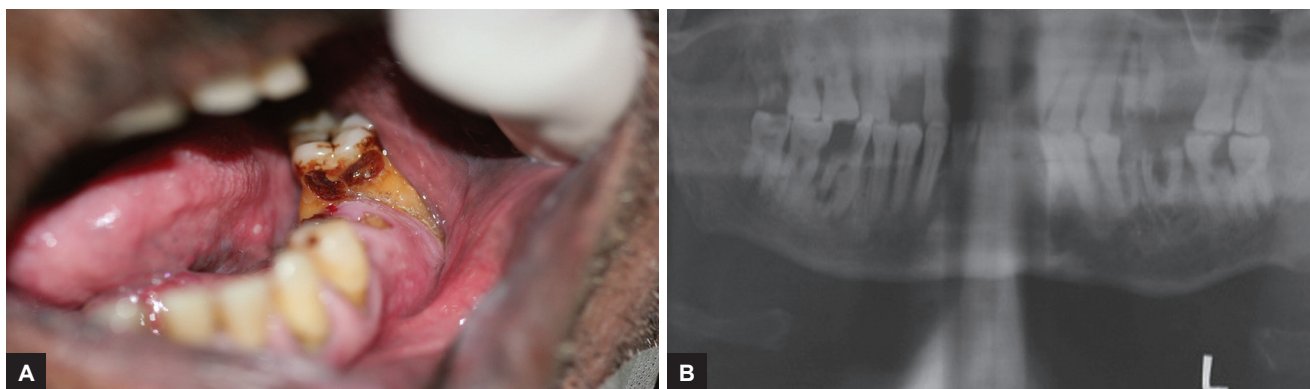
On extraoral examination (Figs 1A and B), there was diffused swelling in the lower third of face measuring approximately 5 × 3 cm extending from left angle of mandible to right angle of mandible with bilateral involvement of the submandibular and sublingual spaces.

The overlying skin appeared reddish, stretched, and shiny. On palpation, the swelling was tender with elevated temperature. Patient had difficulty in breathing and restricted mouth-opening, with an interincisor gap of 1 cm.

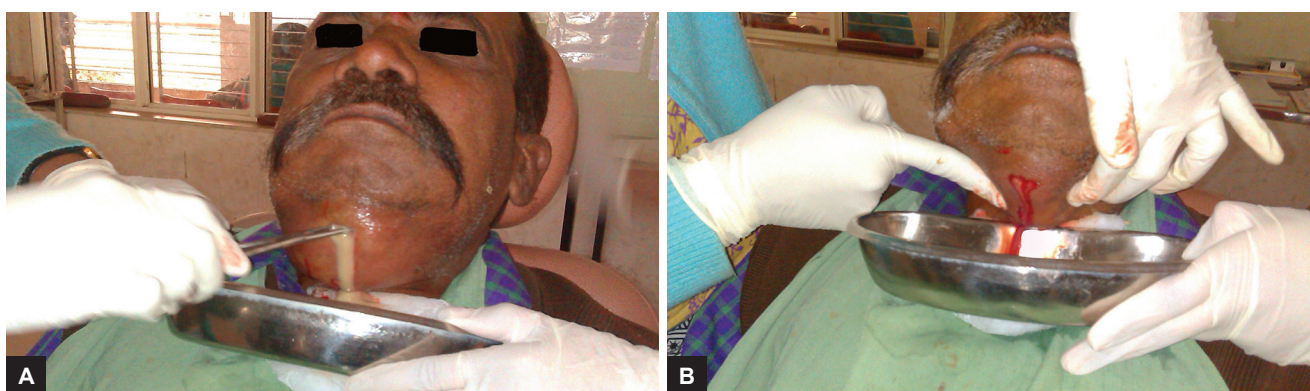
Intraoral examination (Fig. 2A) revealed vestibular swelling and obliteration in the region of 35 (root stump) and 36 with pus discharge from gingival sulcus. Generalized attrition and gingival recession were noted. Orthopantomograph revealed (Fig. 2B) grossly destructed 46, 37, missing 26, and root stumps with 14, 18, 25, 35, 36. Depending on the history and clinical examination, a



Figs 1A and B: Clinical images: (A) Pretreatment; and (B) posttreatment



Figs 2A and B: (A) Intraoral view; and (B) orthopantamograph showing root piece with 35



Figs 3A and B: Incision and drainage of pus

diagnosis of Ludwig's angina was made. Patient was scheduled for emergency drainage (Figs 3A and B) of the abscess followed by intravenous injections of augmentin 1.2 gm twice a day, metrogyl 100 mg thrice a day, and intramuscular injection of voveran 75 mg once a day for 5 days. Patient was recalled after 5 days, the swelling was subsided, and patient was scheduled for further treatment with extraction of 35 and 36 (root stumps) followed by oral prophylaxis and replacement of missing teeth.

DISCUSSION

Ludwig's angina is a serious, potentially life-threatening cellulitis or connective tissue infection of the floor of the mouth that spreads to the structures of the anterior neck and beyond via connective tissue, muscle, and fascial planes rather than by the lymphatic system.³

About 80% of cases of Ludwig's angina are odontogenic in etiology, primarily resulting from infections of the second and third molars. Predisposing factors include intravenous drug use, diabetes mellitus, systemic lupus erythematosus, acute glomerulonephritis aplastic anemia, neutropenia, dermatomyositis, alcoholism, malnutrition, a compromised immune system, organ transplantation, and trauma.⁴

The signs of Ludwig's angina are bilateral involvement of lower facial swelling, pain, and erythema

around the lower jaw and upper neck. This is because the infection has spread to involve the submandibular, sublingual, and submental spaces of the face.³ Swelling in these areas can often push the floor of the mouth, including the tongue upward and backward further compromising the airway. Intraorally, there will be elevation of the tongue, woody, brawny in duration of the floor of the mouth and anterior neck with a bilateral submandibular edema.

Asphyxia is caused by expanding edema of soft tissues of the neck. Additional symptoms include dysphagia, dysphonia, malaise, fever, tiredness, confusion, anxiousness, agitation, earache, drooling of saliva, and fetid breath. There may also be varying degrees of trismus, hoarseness, stridor, respiratory distress, decreased air movement, and cyanosis.⁵

Up to 65% of patients with Ludwig's angina develop suppurative complications that require surgical drainage. Other complications of Ludwig's angina include life-threatening airway narrowing or obstruction, cavernous sinus thrombosis, brain abscess, carotid sheath infection, arterial rupture, suppurative thrombophlebitis of the internal jugular vein, mediastinitis, empyema, lung abscess, pericardial and/or pleural effusion, osteomyelitis of the mandible, subphrenic abscess, septic shock, and aspiration pneumonia.⁶

Ludwig's angina is a life-threatening condition and carries a fatality rate of about 5%. In keeping with this notion, hospitalization should be taken as the initial measure, and treatment should be based on three important aspects that include upper airway maintenance, drainage or surgical decompression, and intravenous antimicrobial therapy.²

Airway management is the foundation of treatment for patients with Ludwig's angina. Recommended techniques include routine incision and drainage, orotracheal intubation, and fiber-optic nasotracheal intubation. A nasotracheal tube is sometimes warranted for ventilation, if the tissues of the mouth make insertion of an oral airway difficult or impossible. In the case of respiratory impairment, the patient should be admitted to the intensive care unit and orotracheal intubation should be postponed. Traditionally, aggressive airway management by securing the airway with endotracheal intubation or surgically with a surgical tracheostomy was the norm.⁷

The use of intravenous steroids has been proposed as a mean of reducing soft tissue swelling and edema and minimizing the likelihood for the need of a surgical airway in Ludwig's angina. This remains controversial, as up to this date no randomized controlled trials that demonstrate the efficacy of corticosteroids in these patients exist.⁶

Antibiotics should be initiated as soon as possible. Antibiotics should initially be broad-spectrum and cover Gram-positive, Gram-negative, and anaerobic organisms. The antibiotic of choice is from the penicillin group. Recommended initial antibiotics are high-dose penicillin G, sometimes used in combination with an antistaphylococcal drug or metronidazole (Table 1).³

Larawin et al⁸ retrospectively studied a total of 103 patients with deep neck space infections from 1993 to 2005. Ludwig's angina was the most commonly encountered infection seen in 38 (37%) patients of treatment. About 13 (34%) patients managed successfully with medical therapy and only 4 (10%) patients required a tracheostomy tube.

Kurien et al reported a 13-year review of patients with Ludwig's angina between 1982 and 1995. Patients were either admitted to the ear-nose-throat or pediatric surgical units. There were 41 patients, 24% being children and 76% adults. In children, 70% were controlled with conservative medical management, while 81% of adults required incision and drainage. Tracheostomy was necessary in 10% of the children and 52% of the adults. Mortality rate was 10% in both groups.⁹

A 9-year review by Greenberg et al¹⁰ of 29 cases of deep neck space infections reported 21 patients (72%) treated conservatively following initial clinical assessment.

Table 1: Management of Ludwig's angina

Sl. no.	Name of drug (injection)	Dosage
1	Benzylpenicillin	1.2 gm IV every 6 hours
2	Metronidazole	Flagyl 100 mg IV thrice daily for 5 days
3	Patients allergic to penicillin-clindamycin hydrochloride	Cleocin HCl 450 mg IV every 8 hours
4	Amoxicillin-clavulanate	Augmentin 1.2 gm IV BID twice daily for 5 days
5	Dexamethasone sodium phosphate	(Decadron) 8–12 mg IV initially then of 4–8 mg every 6 hours given for 48 hours
6	Gentamicine	40 mg IV twice daily for 5 days
7	Voveran	75 mg once daily intramuscular
8	Cefoxitin sodium	Cefoxil
9	Ticarcillin-clavulanate	Timentin
10	Piperacillin-tazobactam	Zosyn

IV: Intravenous

CONCLUSION

Thus, because of its invasive nature, Ludwig's angina needs early recognition and treatment. The appropriate use of parenteral antibiotics, airway protection techniques, and formal surgical drainage of the infection remain the standard protocols of treatment in advanced cases of Ludwig's angina.

REFERENCES

- Kassam K, Messiha A, Heliotis M. Ludwig's angina: the original angina. *Case Rep Surg* 2013 May;2013(974269):1-4.
- Campos MA, Junior Portal ML, Gomes CA, do Amaral KP, Almeida DC. Ludwig's angina after severe thrombocytopenic purpura associated with dengue fever. *Rev Soc Bras Med Trop* 2014 Jan-Feb;47(1):116-118.
- Wadhawan R, Luthra K, Gajjar D, Solanki G. Insight to Ludwig's angina: a review. *Int J Adv Case Rep* 2014 Aug;1(2):78-82.
- Barakate MS, Jensen MJ, Hemli JM, Graham AR. Ludwig's angina, report of a case and review of management issues. *Ann Otol Rhinol Laryngol* 2001 Jun;110(5 Pt 1):453-456.
- Chou YK, Lee CY, Chao HH. An upper airway obstruction emergency. Ludwig angina. *Pediatr Emerg Care* 2007 Dec;23(12):892-896.
- Chuang K, Clinkard DJ, Enepekides D, Peerbaye Y, Lin VYW. An unusual presentation of Ludwig's angina complicated by cervical necrotizing fasciitis: a case report and review of the literature. *Case Rep Otolaryngol* 2012 Jun;(2012), Article ID 931350:4 pages.
- Hasan W, Leonard D, Russell J. Ludwig's angina – a controversial surgical emergency: how we do it. *Int J Otolaryngol* 2011 Apr;2011(231816):1-4.
- Larawin V, Naipao J, Dubey SP. Head and neck space infections. *Otolaryngol Head Neck Surg* 2006 Dec;135(6):889-893.
- Kurien M, Mathew J, Job A, Zachariah N. Ludwig's angina. *Clin Otolaryngol Allied Sci* 1997 Jun;22(3):263-265.
- Greenberg SL, Huang J, Chang RS, Ananda SN. Surgical management of Ludwig's angina. *ANZ J Surg* 2007 Jul;77(7):540-543.